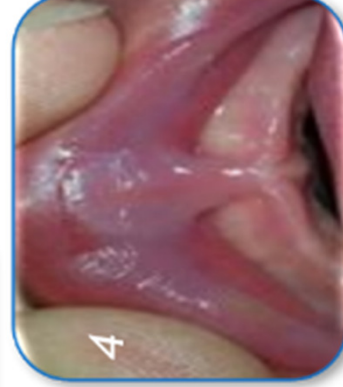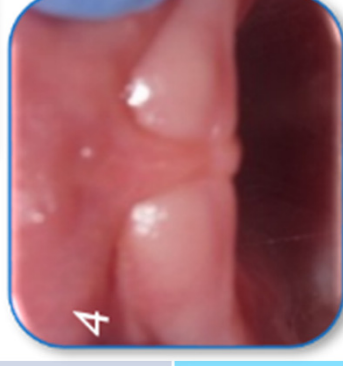
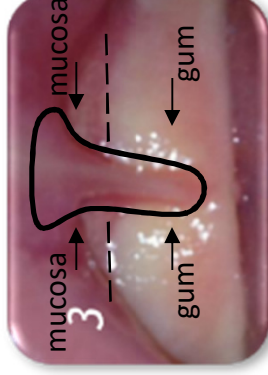
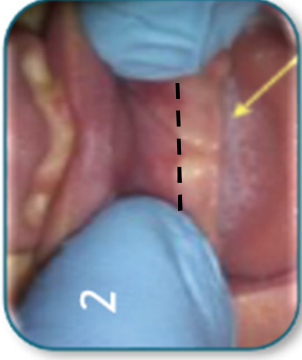
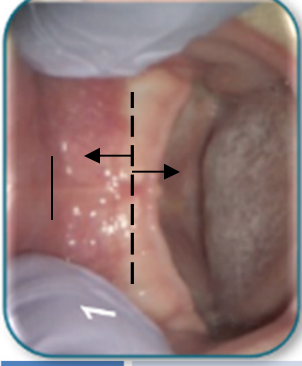


# Anatomy & Classification

## Maxillary Labial Frenum

	Clinical signs	Tx consideration
Class I	Minimal visible attachment	No tx indicated.
Class II	Attachment primarily into the gingival tissue	Monitor closely.
Class III	Inserts just in front of anterior papilla	Tx consideration based on infant and maternal factors
Class IV	Attachment into the hard palate or papilla area	Tx consideration based on infant and maternal factors

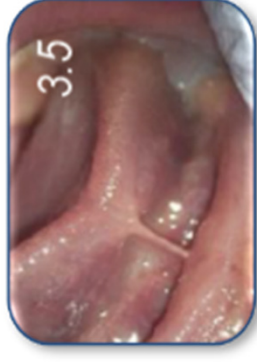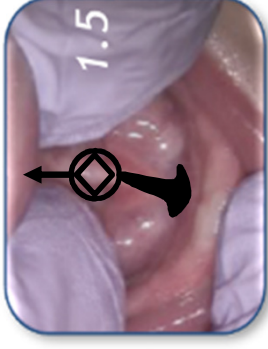
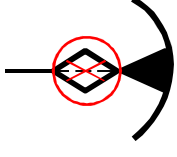
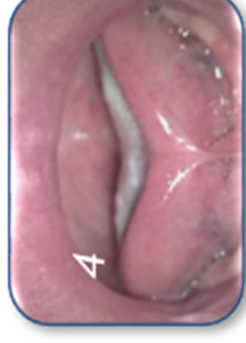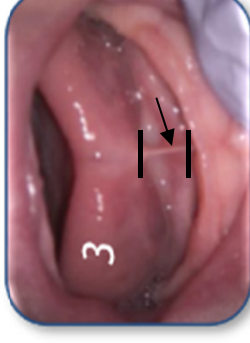


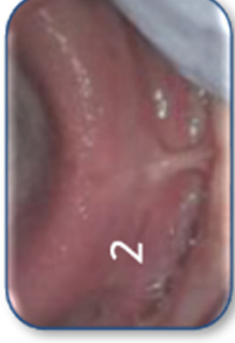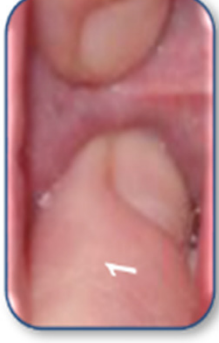\* Based on Kotlow, L. Lasers in Pediatric Dentistry. Dent Clin N Am 48 (2004), 889-922.

# Anatomy & Classification

## Lingual Frenum

	Clinical signs	Tx consideration
Class I	Posterior area which may not be obvious and only palpable, some are submucosally	Tx needed if infant and maternal factors
Class II	Distal to the midline. Tongue still appear normal	Tx needed if infant and maternal factors
Class III	Midline-area under tongue (creating a hump or cupping of tongue)	Tx needed for infant and maternal factors
Class IV	Total tip involvement	Tx needed for infant and maternal factors



\* Based on Kotlow, L. Lasers in Pediatric Dentistry. Dent Clin N Am 48 (2004), 889-922.